


# A case of aortic valve leaflet tear and perforations after neocuspidization

Masato Makino<sup>1</sup>, Hiroyuki Yamamoto<sup>2\*</sup> , Hatsue Ishibashi-Ueda<sup>3</sup> and Yoshitsugu Nakamura<sup>4</sup>

<sup>1</sup>Department of Cardiology, Chiba-Nishi General Hospital, Matsudo, Japan; <sup>2</sup>Department of Cardiology, Cardiovascular Center, Showa General Hospital, Kodaira, Tokyo, Japan; <sup>3</sup>Department of Pathology, National Cerebral and Cardiovascular Center, Suita, Japan; <sup>4</sup>Department of Cardiovascular Surgery, Chiba-Nishi General Hospital, Matsudo, Japan

## Abstract

Although aortic valve (AV) replacement is a curative procedure for severe aortic stenosis, prosthetic heart valves have many disadvantages and cause serious complications. A new promising surgical procedure—aortic valve neocuspidization (AVNeo)—has recently been developed; it is an original method of AV reconstruction with autologous pericardium. It has been reported to yield excellent medium-term results with respect to durability and complications. Herein, we encountered a first case of AV leaflet tear and perforations 27 months after AVNeo using autologous pericardium. AV leaflet tear or perforation is well recognized as a long-term serious complication of pericardial xenografts. Interestingly, however, AVNeo caused early structural valve deterioration in the current case. In the present case, an eccentric aortic regurgitation jet observed on colour flow imaging led us to reach the correct diagnosis. Finally, the patient showed complete recovery with redo AV replacement. This case highlights the importance of understanding the potential pitfalls of this new surgical technique and that of colour Doppler echocardiography in reaching a definite diagnosis.

**Keywords** Aortic valve neocuspidization using autologous pericardium; Aortic regurgitation; Aortic valve leaflet tear and perforations; Colour Doppler echocardiography; Structural valve deterioration

Received: 11 November 2018; Accepted: 17 January 2019

\*Correspondence to: Hiroyuki Yamamoto, Department of Cardiology, Cardiovascular Center, Showa General Hospital, 8-1-1 Hanakoganei, Kodaira, Tokyo 187-8510, Japan. Tel: +81 42 461 0052; Fax: +81 42 464 7912. Email: hyamamoto19700908@gmail.com

## Introduction

Symptomatic aortic stenosis (AS) is life threatening if left untreated, and its incidence has been steadily increasing, because the population is ageing. Although surgical aortic valve (AV) replacement can cure severe AS, prosthetic heart valves have many disadvantages and lead to serious complications including thromboembolism, anticoagulation-related bleeding, and structural valve deterioration (SVD).<sup>1</sup> Recently, a new promising surgical procedure of aortic valve neocuspidization (AVNeo) using autologous pericardium (AP) has been reported to yield extremely excellent medium-term (5–10 years) results with regard to durability and complications.<sup>2,3</sup> Briefly, this procedure utilizes glutaraldehyde-treated AP to replace AV leaflets and includes the following steps: first, the pericardium is dissected and treated with a 0.6% glutaraldehyde solution. The diseased

leaflets are carefully excised. Next is to measure the distance between each commissure and trim the pericardium according to the leaflet size. Lastly, the pericardial leaflet is sutured to each annulus. A study of 404 consecutive cases who underwent AVNeo procedure reported that freedom from re-operation was 96.2% at 53 month follow-up. Post-operative echocardiography revealed less than mild aortic regurgitation (AR) and a low gradient across the AV at 3.5 year follow-up.<sup>4</sup>

## Case report

An 85-year-old woman was referred to our hospital for management of intractable heart failure. Twenty-seven months previously, she had undergone AVNeo with AP for severe AS. She had no history of infective endocarditis or chest

trauma. During physical examination, she had a blood pressure of 114/41 mmHg, a grade 3/6 diastolic murmur, and pre-tibial oedema. A chest X-ray scan revealed cardiomegaly and pulmonary oedema. Transthoracic Doppler echocardiography showed severe AR with an eccentric posterior jet (Figure 1A and B, arrow; Supporting Information, Movies S1 and S2). Right heart catheterization showed a mean pulmonary arterial pressure of 35 mmHg and pulmonary wedge pressure of 23 mmHg, confirming severe pulmonary hypertension due to left heart disease. The transaortic valve pressure gradient was 2 mmHg. Moreover, transoesophageal echocardiography showed a flap in the middle of the free margin (Figure 1C, arrowhead; Supporting Information, Movie S3) and an eccentric posterior jet in the left coronary cusp (Figure 1D, arrow; Supporting Information, Movie S4). Thus, the patient was suspected of having severe AR due to AV leaflet tear and perforation. She underwent a repeat of the minimally invasive AV replacement. Cardiopulmonary bypass was established via peripheral cannulation. The ascending aorta was clamped and opened through a 6 cm thoracotomy incision in the 3rd intercostal space. Selective cardioplegia was given through bilateral coronary orifices. Visual examination of the reconstructed cusps confirmed a radial tear (arrowhead) and two perforations (arrows) in the left coronary cusp (Figure 1E–G). Pathological examination of the AP valve showed collagen degeneration, separation, serum insudation, and reactive inflammatory infiltration, suggesting SVD. Notably, oedematous lesions without remarkable calcification or vegetation were observed at the tear lesion (Figure 1H). Post-operative echocardiography revealed a significant reduction in AR grade (from severe to none) and a marked reduction in systolic pulmonary artery pressure (from 61 to

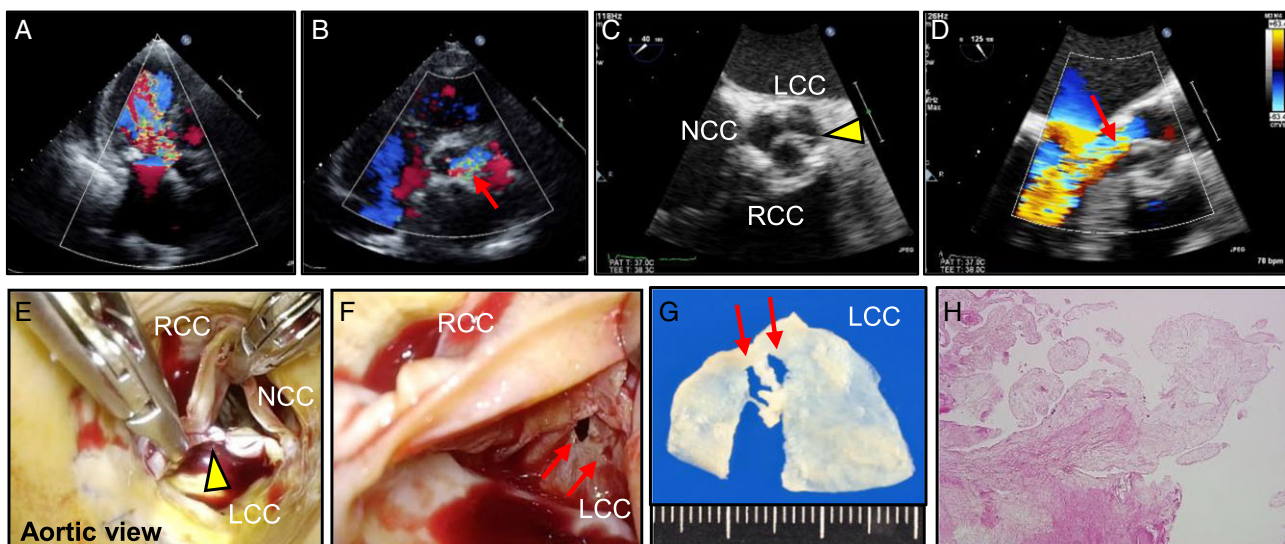
39 mmHg) at 1 month follow-up. The signs and symptoms of heart failure resolved dramatically.

## Discussion

The novel procedure of AVNeo using AP has been developed only recently.<sup>2</sup> Its main features are its compatibility with living tissue and considerable advantages over prosthetic heart valves, because foreign materials need not be used. Moreover, its indications expand from AS to a wide range of AV diseases including AR, infective endocarditis, and annuloaortic ectasia. The medium-term results are excellent, with no serious complications such as moderate or severe AS or AR 5 years after surgery.<sup>4</sup> Thus, the number of AVNeo procedures conducted in recent times has been increasing exponentially. To our knowledge, this report presents the first case of severe AR due to AV leaflet tear and perforations related to AVNeo.

The AVNeo technique has two unique characteristics. First, it utilizes glutaraldehyde-treated AP, whose tensile strength is four times that of native leaflets, thereby ensuring durability.<sup>5</sup> Second, the contact point of new pericardial cusps is designed to be as high as the horizontal commissure in order to yield a large coaptation zone and reduce the mechanical stress on the commissure. In the present case, considering that the leaflet tear was near the cusp's contact point, the new AV leaflets themselves may have caused damage to one another as a result of physical contact. The pathological findings also indicate that damage associated with mechanical stress may have been related to the original design of

**Figure 1** (A, B) Transthoracic echocardiography. (C, D) Transoesophageal echocardiography. (E, F) Intraoperative view of neo-aortic valve. (G) The removed left coronary cusp (LCC). (H) The pathological view ( $\times 100$ ). RCC, right coronary cusp; NCC, non-coronary cusp.



the leaflets. Leaflet tear or leaflet perforation has often been reported as a long-term complication of pericardial xenografts, and it may cause SVD requiring reoperation.<sup>6</sup> It is extremely rare that it occurs within 5 years after implantation, because the changes gradually occur over 10 years; this may have happened in the present case. Further investigation will be needed with regard to the mechanism of SVD and the long-term durability of AVNeo with AP.

The eccentric AR jet observed on colour flow imaging led us to suspect AV leaflet tear or perforation in the present case.<sup>7</sup> Transoesophageal echocardiography can provide more information about the location, severity, and mechanism of AR.<sup>8</sup> Even if AR is not apparent immediately after cardiac surgery, post-operative valve leaflet tear or perforation can develop anytime or progress over time. Therefore, cardiac evaluation with colour Doppler echocardiography is recommended for any patient with a history of any prior cardiac valvular intervention who presents with new-onset or worsening heart failure.

In conclusion, we described, to our knowledge, the first case of AV leaflet tear and perforations that presented 27 months after AVNeo using AP in a patient who developed significant AR requiring AV replacement. Colour Doppler echocardiography was useful to reach a definitive diagnosis.

## Conflict of interest

None declared.

## References

1. Nishimura RA, Otto CM, Bonow RO, Carabello BA, Erwin JP 3rd, Guyton RA, O'Gara PT, Ruiz CE, Skubas NJ, Sorajja P, Sundt TM 3rd, Thomas JD, American College of Cardiology/American Heart Association Task Force on Practice Guidelines. 2014 AHA/ACC guideline for the management of patients with valvular heart disease: a report of the American College of Cardiology/American Heart Association Task Force on Practice Guidelines. *J Am Coll Cardiol* 2014; **63**: e57–e185.
2. Ozaki S, Kawase I, Yamashita H, Uchida S, Takatoh M, Kiyohara N. Midterm outcomes after aortic valve neocuspidization with glutaraldehyde-treated autologous pericardium. *J Thorac Cardiovasc Surg* 2018; **155**: 2379–2387.
3. Ozaki S, Kawase I, Yamashita H, Uchida S, Nozawa Y, Matsuyama T, Takatoh M, Hagiwara S. Aortic valve reconstruction using self-developed aortic valve plasty system in aortic valve disease. *Interact Cardiovasc Thorac Surg* 2011; **12**: 550–553.
4. Ozaki S, Kawase I, Yamashita H, Uchida S, Nozawa Y, Takatoh M, Hagiwara S. A total of 404 cases of aortic valve reconstruction with glutaraldehyde-treated autologous pericardium. *J Thorac Cardiovasc Surg* 2014; **147**: 301–306.
5. Yamashita H, Ozaki S, Iwasaki K, Kawase I, Nozawa Y, Umezumi M. Tensile strength of human pericardium treated with glutaraldehyde. *Ann Thorac Cardiovasc Surg* 2012; **18**: 434–437.
6. Machida H, Ishibashi-Ueda H, Nakano K, Sasako Y, Kobayashi J, Bando K, Minatoya K, Imamura H, Kitamura S. A morphologic study of Carpentier–Edwards pericardial xenografts in the mitral position exhibiting primary tissue failure in adults in comparison with Ionescu–Shiley pericardial xenografts. *J Thorac Cardiovasc Surg* 2001; **122**: 649–655.
7. Hill AC, Bansal RC, Razzouk AJ, Liu M, Bailey LL, Gundry SR. Echocardiographic recognition of iatrogenic aortic valve leaflet perforation. *Ann Thorac Surg* 1997; **64**: 684–689.
8. Ballal RS, Mahan EF 3rd, Nanda NC, Sanyal R. Aortic and mitral valve perforation: diagnosis by transesophageal echocardiography and Doppler color flow imaging. *Am Heart J* 1991; **121**: 214–217.

## Author Contributions

M.M. and H.Y. prepared the clinical design and concept; M.M., H.Y., H.I.-U., and Y.N. involved in the acquisition of clinical data; H.Y., H.I.-U., and Y.N. analysed and interpreted the data; and H.Y. wrote the manuscript. All authors discussed, read, and approved the submission of this manuscript to the journal.

## Consent

The authors confirm that written consent for submission and publication of this case report including images and the associated movie has been obtained from the patient.

## Supporting information

Additional supporting information may be found online in the Supporting Information section at the end of the article.

**Movie S1.** Transthoracic echocardiography: apical three-chamber view with color Doppler.

**Movie S2.** Transthoracic echocardiography: parasternal short-axis view with color Doppler.

**Movie S3.** Transoesophageal echocardiography: short-axis view.

**Movie S4.** Transoesophageal echocardiography: long-axis view with color Doppler.