

Left Internal Thoracic Artery Graft Assessment by Firefly Fluorescence Imaging for Robot-Assisted Minimally Invasive Direct Coronary Artery Bypass

Innovations
2019, Vol. 14(2) 144–150
© The Author(s) 2019
Article reuse guidelines:
sagepub.com/journals-permissions
DOI: 10.1177/1556984519836810
journals.sagepub.com/home/inv



Yoshitsugu Nakamura¹, MD, PhD, Miho Kuroda¹, MD, Yujiro Ito¹, MD, Takahiko Masuda¹, MD, Shuhei Nishijima¹, MD, Takahisa Hirano¹, MD, and Shinichi Hisasue², MD, PhD

Abstract

Objective: The da Vinci Xi surgical system (Intuitive Surgical, Sunnyvale, CA, USA) cannot give tactile feedback to surgeons. This shortcoming may increase the risk of left internal thoracic artery (LITA) injury during its harvest. We utilized Firefly Fluorescence Imaging (Firefly) to assess LITA quality in robot-assisted minimally invasive direct coronary artery bypass (R-MIDCAB). **Methods:** We retrospectively reviewed clinical records and intraoperative videos of 30 consecutive patients who underwent R-MIDCAB with LITA–left anterior descending (LAD) coronary bypass. All patients had post-harvest assessment of LITA blood flow by Firefly with 1 mL (2.5 mg/mL) of indocyanine green injection through a central line. **Results:** Twenty-seven of the patients were male, mean age was 67.7 ± 10.7 years. In post-harvest assessment performed before transection of the distal LITA, blood flow in LITA was well visualized in 28 patients. In the remaining 2 patients, 1 had dissection and the other had severe spasm of the LITA. Firefly was also useful for locating LITA and LAD and for assessing blood flow of the graft after anastomosis. Time required for each Firefly assessment was approximately 20 seconds. There were no side effects or complications due to Firefly intraoperatively and postoperatively. Twenty-six patients had postoperative coronary computed tomography; LITA patency rate was 100% (26/26). **Conclusion:** Firefly is fast, simple, and effective for locating and assessing flow in LITA and LAD before and after anastomosis in R-MIDCAB.

Keywords

minimally invasive cardiac surgery, robot, internal thoracic artery, coronary artery bypass grafting

Introduction

The quality of the left internal thoracic artery (LITA) is a critical factor for successful bypass grafting in minimally invasive direct coronary artery bypass (MIDCAB) through left mini-thoracotomy.^{1,2} Robot-assisted LITA harvesting further reduces invasiveness of MIDCAB (R-MIDCAB). However, current surgical robots do not give tactile feedback to surgeons. This shortcoming may increase the risk of LITA injury. Therefore, we utilized a newly developed system, Firefly Fluorescence Imaging (Firefly), to assess LITA quality in R-MIDCAB. Firefly is one of the imaging systems of the da Vinci robotic surgical system (Intuitive Surgical, Sunnyvale, CA, USA). Firefly's imaging system utilizes the properties of indocyanine green (ICG). The ICG molecule binds to plasma proteins in the blood, and when infrared wavelength light is shone on it, it absorbs the light and emits a longer wavelength light, which can be captured by a robotic near-infrared camera.³ This is how

¹Department of Cardiovascular Surgery, Chiba-Nishi General Hospital, Matsudo, Japan

²Department of Urology, Chiba-Nishi General Hospital, Matsudo, Japan

Corresponding Author:

Yoshitsugu Nakamura, Department of Cardiovascular Surgery, Chiba-Nishi General Hospital, Matsudo, Japan.

Email: ystgnkmr@gmail.com

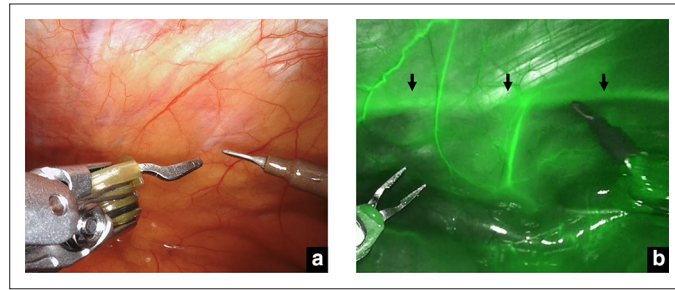


Fig. 1. Example of Firefly Fluorescence Imaging use in localizing arterial position. (a) Left internal thoracic artery is not visible through the muscle and pleural fat. (b) Firefly Fluorescence Imaging reveals its location (arrows).

Firefly provides real-time images of vasculature and blood flow in the LITA before harvesting and bypass completion. In this study, we retrospectively reviewed intraoperative Firefly images and assessed the efficacy of Firefly in R-MIDCAB.

Methods

The intraoperative usage of Firefly was approved by the institutional review board. We retrospectively reviewed the clinical records and intraoperative videos of 30 patients who underwent R-MIDCAB. The patients were anesthetized using a double-lumen endotracheal tube to enable selective single-lung ventilation. We used the da Vinci Xi surgical system with Firefly (Intuitive Surgical, Sunnyvale, CA, USA).

Technical Procedure

The patients were anesthetized using a double-lumen endotracheal tube to enable selective single-lung ventilation. A robotic camera port is created in the fourth intercostal space on the anterior axillary line in the left chest, and carbon dioxide insufflation is used to maintain an intrapleural pressure of 6 to 12 mmHg. The left and right ports and robotic arms are placed in the second and the sixth intercostal spaces, respectively.

If LITA is not visible before harvesting through the endothoracic fascia at this stage, Firefly is used to locate the LITA. ICG is administered through a central line (1 mL, 2.5 mg/mL). The LITA becomes visible as a green line if intensity of Firefly is strong enough to be seen through the endothoracic fascia (Fig. 1). This enables surgeons to minimize the scope of dissection and decreases the chance of LITA injury.

LITA is harvested in a skeletonized fashion by cauterizing side branches close to the chest wall by robotic electrocautery. After the part of the LITA to be harvested is isolated from the thoracic wall, the pericardium is opened by robotic electrocautery. Blood flow and patency of LITA is assessed by Firefly with 1 mL of ICG. The coronary target (position and geometry of the LAD and its branches) can be confirmed by Firefly at the same time if necessary (Fig. 2).




Fig. 2. Left anterior descending artery and diagonal branch visualized by Firefly Fluorescence Imaging.

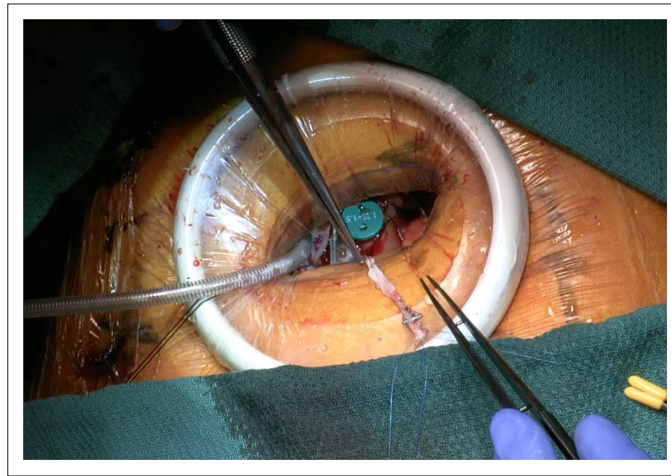


Fig. 3. Small thoracotomy for anastomosis. Only the distal 2 to 3 cm of the left internal thoracic artery can be seen by the naked eye because of the small aperture.

Once the suitability of LITA is confirmed by Firefly, Heparin is given. LITA is clamped and cut between them using robotic Potts scissors and fixed on the pericardium so it is not lost in the left chest cavity.

Then a 4-cm incision is made in the fourth intercostal space with a non-rib-spreading technique that only uses a soft tissue retractor (Fig. 3). LITA is anastomosed to the LAD in normal end-to-side fashion. Our default is to use transit time flowmetry for graft assessment, but when the result is not satisfactory, Firefly can be additionally utilized to assess blood flow in LITA by manually inserting the robotic scope through the mini-thoracotomy.

Results

Between March 2017 and August 2018, 30 MIDCAB cases underwent intraoperative Firefly LITA assessment. Of those, 27 patients were male. Mean age (SD) was 67.7 ± 10.7 years. Preoperative characteristics are summarized in Table 1.

Average total procedure time was 202 ± 52 minutes. Average LITA harvesting time was 54 ± 12 minutes. Intraoperative data are summarized in Table 2.

Table 1. Preoperative Patient Characteristics.

N = 30	n (%)
Age	67.7 ± 10.7
Male	27 (90)
Hypertension	24 (80)
Hyperlipidemia	18 (60)
Diabetes mellitus	9 (30)
Smoking history	20 (67)
Ejection fraction	60.5 ± 14.1
LAD single lesion	9 (30)
CTO	6 (20)
Prior PCI	4 (13)
Multivessel lesion	21 (70)
SYNTAX score	24.1 ± 7.8

CTO, chronic total occlusion; LAD, left anterior descending artery; PCI, percutaneous coronary intervention; SYNTAX, Synergy between PCI with Taxus and Cardiac Surgery.

Table 2. Intraoperative Data.

N = 30	n (%)
Total procedure time	202 ± 52
LITA harvesting time	54 ± 12
LITA–LAD flow (mL/minute)	29 ± 17
LITA injury (dissection)	1 (3)
Anastomosis revision	1 (3)
Conversion to sternotomy	0
Blood transfusion	0

LAD, left anterior descending artery; LITA, left internal thoracic artery.

Seven patients required pre-harvest LITA evaluation with Firefly, because LITA was not visible to the naked eye, buried in the pleural muscle and fat. The entire length of the LITA became visible through the pleural muscle and fat by Firefly in all 7 cases (Fig. 1) leading to efficient harvesting of the LITA with minimal incision of the chest wall.

All 30 patients had post-harvest assessment before transection of the distal LITA (Table 3). LITA blood flow was well visualized in 28 patients (Fig. 4, online Supplemental Video 1). In those patients, pulsation of LITA at the distal end and free flow were also assessed after transection of LITA. Both of them were deemed adequate for bypass. In the remaining 2 patients, 1 patient had a hematoma in the midportion of the LITA. The Firefly image of the LITA showed a to-and-fro pattern of blood flow on the side proximal to the hematoma (Fig. 5, online Supplemental Video 2). A left thoracotomy was made. After transection of LITA, there was no blood flow from the distal end of LITA; therefore, LITA was cut longitudinally from the distal to the proximal part to investigate the cause of the no-flow. LITA was found to have a dissection at the hematoma part. Blood flow at the proximal side was normal. Hence, the LITA was transected at the side proximal to the dissection and extended by a radial artery through the thoracotomy. The composite graft with the LITA and radial artery was anastomosed to the LAD. In the other patient, no blood flow was seen initially. However, no injury was found in the entire length of the LITA by robotic camera. We then transected the LITA and evaluated free flow through the left thoracotomy incision length of 4 cm. It was extremely poor in the beginning. We increased the blood pressure and rinsed LITA with warm papaverine solution. This measure improved the blood flow until it became suitable for grafting. The position and geometry of the LAD as well as its diagonal branches were visualized by Firefly in all 30 cases (Fig. 2).

In 4 patients, graft flow assessed by transit time flowmetry was low (less than 15 mL/minute). Firefly was used to evaluate LITA graft patency in these patients. Three of them had good blood flow according to Firefly, but 1 patient had no blood flow. We revised the LITA–LAD anastomosis in that patient, which improved graft flow according to Firefly (Fig. 6). Postoperative coronary computed tomography showed LITA was patent in all patients.

Time required for Firefly was approximately 15 seconds each time. There was no side effect or complication due to Firefly intraoperatively and postoperatively. There was no hospital death, nor a major complication. In the 26 patients we conducted postoperative coronary computed tomography on, LITA was patent in all (26/26). The remaining 4

Table 3. Success Rate of Assessment by Firefly Fluorescence Imaging.

	n (%)
Pre-harvesting LITA evaluation	7 (100)
Post-harvesting LITA evaluation	30 (100)
Intact LITA	28
Dissection	1
Spasm with poor flow	1
LAD position assessment	30 (100)
LITA–LAD anastomosis	4 (100)
Complication associated with Firefly	0

LAD, left anterior descending artery; LITA, left internal thoracic artery.

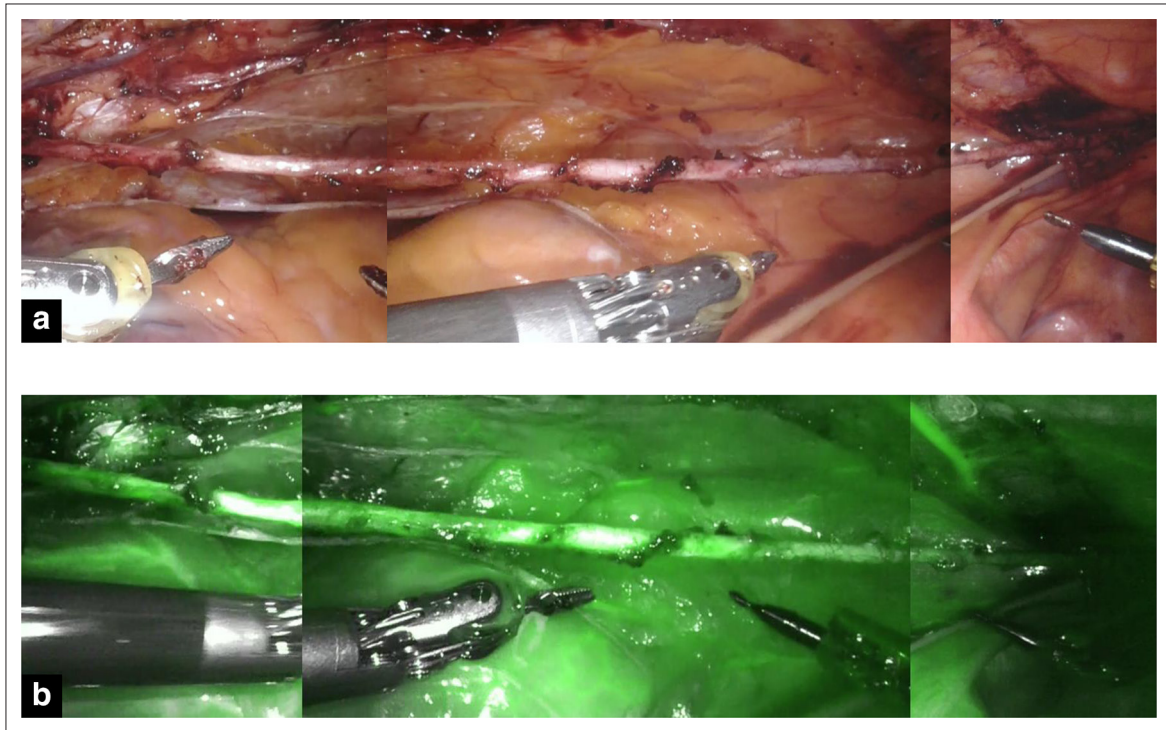


Fig. 4. Entire length of left internal thoracic artery. (a) Ordinary camera view. (b) Firefly Fluorescence Imaging camera view.

patients who did not have coronary computed tomography due to concern for their chronic kidney disease did well and had no chest symptoms postoperatively.

Discussion

The quality of LITA is the most important factor for the success of coronary artery bypass grafting. In conventional coronary artery bypass grafting through median sternotomy, adequacy of the flow in LITA is assessed by allowing free flow from the cut end. If flow seems insufficient, surgeons can further assess its suitability by careful visual inspection

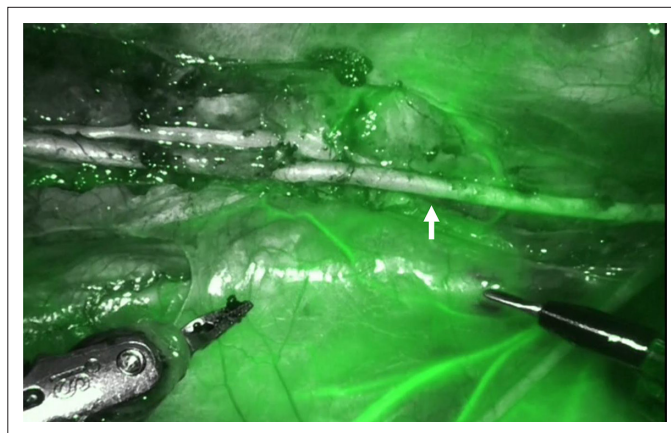


Fig. 5. Still photo of blockage in a left internal thoracic artery. The artery to the right of the blockage fluoresces, but the left portion does not. The arrow indicates the watershed point of blood flow.

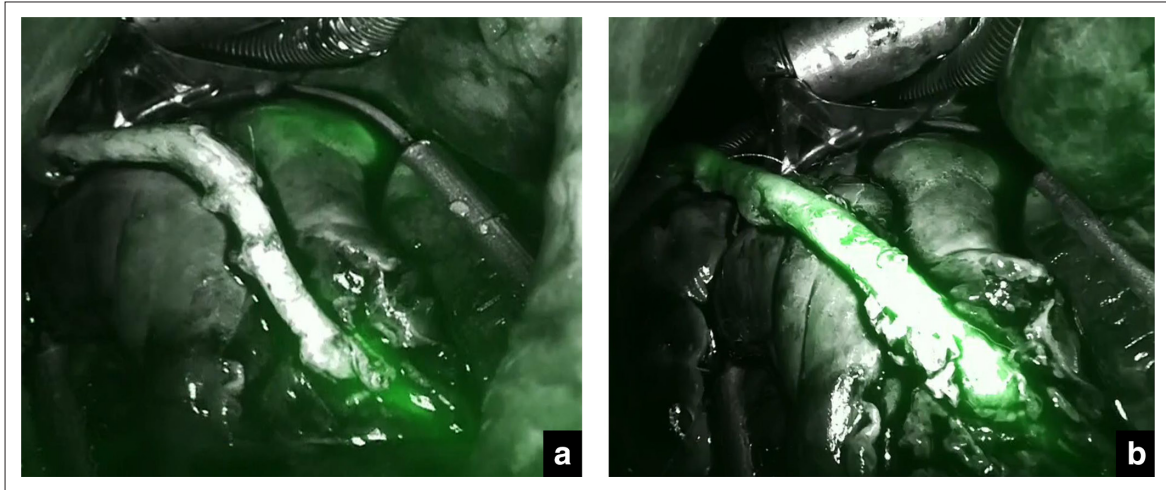


Fig. 6. (a) Poor blood flow in a left internal thoracic artery. (b) After revision of anastomosis, the left internal thoracic artery lit up, indicating improved blood flow.

and by feeling for the pulse along the entire length of LITA. If the LITA seems problematic, repair is attempted, and if that fails, the LITA is abandoned.

In R-MIDCAB, robotic LITA harvesting can be technically demanding due to lack of tactile feedback; nevertheless, it is impossible to inspect or palpate the LITA through the small thoracotomy except for the distal 2 to 3 cm of it (Fig. 3). Hence, if its free flow seemed inadequate, surgeons were unable to judge its suitability for use as a graft.

To overcome these disadvantages of R-MIDCAB, we utilized Firefly in 4 ways. First, LITA suitability was assessed in all 30 patients. When sufficient blood flow was visualized in LITA by Firefly, the LITA was judged to be available for grafting. When a to-and-fro flow pattern was observed, we interpreted that to mean LITA had severe stenosis or occlusion. When no blood flow was visualized, we thought there was a possibility of LITA spasm. Second, LITA location was determined through the pleural muscle and fat by Firefly when it could not be found by regular inspection. In all the 7 patients in whom this was the case, Firefly was able to locate LITA through the pleural muscle and fat. Third, LAD position and its shape were also confirmed by Firefly in all 30 patients. This is crucial because a large diagonal branch could be mistaken for the LAD buried in epicardial fat.⁴ Especially, when carbon dioxide insufflation was used, the position of the heart sometimes changed from that in the preoperative computed tomography image. This may lead the surgeon to mistake the diagonal branch for the LAD. Finally, LITA patency was confirmed by Firefly after completion of LITA–LAD anastomosis. In this study, 4 patients had poor blood flow according to transit flowmetry, so patency was investigated by Firefly. Based on the Firefly results, we revised the anastomosis in 1 patient.

In addition, Firefly assessment in R-MIDCAB was a safe and simple technique requiring only 15 seconds. There was no side effect of ICG and no complication due to Firefly.

This study is the first report to use Firefly for graft assessment in cardiac surgery to the best of our knowledge, although Firefly is widely used in robotic surgery in fields other than cardiac surgery such as urological, hepatic, and gastrointestinal surgery to identify not only vessels, but also tumors, hepatobiliary ducts, and lymph nodes.⁵ Fluorescence imaging itself is not new and was first introduced for intraoperative graft patency assessment after graft anastomosis in coronary artery bypass grafting in 2003 by Taggart and colleagues.⁶ Later it was reported that fluorescence imaging provided images comparable to angiography in quality.⁷ Although other studies have demonstrated the feasibility of high-quality fluorescence imaging,^{8,9} it has not become popular because it doesn't provide quantitative data the way flowmetry does, and it is costly and time-consuming. However, the da Vinci Xi surgical system once purchased, can be utilized in non-robotic cases. For example, one could ignore the system's robotic capability and position the scope manually and employ the Firefly imaging module to identify blood flow quality in any coronary artery bypass surgery that would benefit from fluorescence imaging. A case in point is saphenous vein grafting.

In conclusion, Firefly is simple and effective for assessing LITA quality in R-MIDCAB. Firefly contributes to improve patency of LITA–LAD bypass in R-MIDCAB.

Declaration of Conflicting Interests

The author(s) declared no potential conflicts of interest with respect to the research, authorship, and/or publication of this article.

Funding

The author(s) received no financial support for the research, authorship, and/or publication of this article.

Supplemental Material

Supplemental material for this article is available online.

References

1. Wang X-W, Qu C, Huang C, Xiang X-Y, Lu Z-Q. Minimally invasive direct coronary bypass compared with percutaneous coronary intervention for left anterior descending artery disease: a meta-analysis. *J Cardiothorac Surg.* 2016;11(1):125.
2. Buttar SN, Yan TD, Taggart DP, Tian DH. Long-term and short-term outcomes of using bilateral internal mammary artery grafting versus left internal mammary artery grafting: a meta-analysis. *Heart.* 2017;103(18):1419–1426.
3. Tobis S, Knopf J, Silvers C, Yao J, Rashid H, Wu G, Golijanin D. Near infrared fluorescence imaging with robotic assisted laparoscopic partial nephrectomy: initial clinical experience for renal cortical tumors. *J Urol.* 2011;186(1):47–52.
4. Sato K, Kosakai H, Kumabe S, Nakamura S, Anzai H, Tezuka N, Nakajima R. [Mistaken grafting to diagonal branch in minimally invasive direct coronary artery bypass: a case required reoperation]. *Kyobu Geka.* 2000;53(5):408–411.
5. Gudeloglu A, Brahmabhatt JV, Parekattil SJ. Robotic-assisted microsurgery for an elective microsurgical practice. *Semin Plast Surg.* 2014;28(1):011–019.
6. Taggart DP, Choudhary B, Anastasiadis K, Abu-Omar Y, Balacumaraswami L, Pigott DW. Preliminary experience with a novel intraoperative fluorescence imaging technique to evaluate the patency of bypass grafts in total arterial revascularization. *Ann Thorac Surg.* 2003;75(3):870–873.
7. Reuthebuch O, Häussler A, Genoni M, Tavakoli R, Odavic D, Kadner A, Turina M. Novadaq SPy: intraoperative quality assessment in off-pump coronary artery bypass grafting. *Chest.* 2004;125(2):418–424.
8. Takahashi M, Ishikawa T, Higashidani K, Katoh H. SPY: an innovative intra-operative imaging system to evaluate graft patency during off-pump coronary artery bypass grafting. *Interact Cardiovasc Thorac Surg.* 2004;3(3):479–483.
9. Hatada A, Okamura Y, Kaneko M, Hisaoka T, Yamamoto S, Hiramatsu T, Nishimura Y. Comparison of the waveforms of transit-time flowmetry and intraoperative fluorescence imaging for assessing coronary artery bypass graft patency. *Gen Thorac Cardiovasc Surg.* 2011;59(1):14–18.